



**PATIENT**

Daisy Davila

**SPECIES**

Canine

**BREED**

Chihuahua Mix

**SEX**

Female Spayed

**AGE**

7 years

**WEIGHT**

6.69lbs

**PRESENTING CLINICAL SIGNS**

History: Daisy is referred to evaluate a heart murmur. She is clinically doing well with a good appetite and activity level. Needs dental prophylaxis. On exam: occasional arrhythmia, grade II/VI murmur with PMI left apical area, PSS, lung fields clear, mm pink, moist, CRT < 2. BP: 180mmHg. Currently, no medications. \*Sedated with propofol for study

**ECHOCARDIOGRAM FINDINGS**

2D, m-mode, color flow and Doppler imaging is available.

**Left ventricle:** The LV diameter is normal with adequate myocardial function. LV wall thicknesses are normal.

**Left atrium:** The left atrium is normal.

**Mitral valve:** The mitral valve is mildly thickened with no prolapse into the left atrial lumen. Mild eccentric mitral regurgitation.

**Aortic valve/aorta:** The aortic valve is normal in morphology and mobility. Normal aortic outflow velocity; laminar flow. No aortic insufficiency.

**Right ventricle:** Normal right ventricular diameter and morphology indicating no overt evidence of pulmonary arterial hypertension.

**Right atrium:** Normal RA dimension.

**Tricuspid valve:** The tricuspid valve appears normal with no tricuspid regurgitation.

**Pulmonic valve/pulmonary artery:** The pulmonic valve is normal in morphology and mobility. No pulmonic insufficiency. Normal RVOT velocity; laminar flow.

**Pericardium/other:** No pericardial or pleural effusion noted. No obvious cardiac masses.

**Heart rhythm:** ECG reveals a sinus rhythm with an average HR of 110bpm.

**INTERPRETED BY**

Maggie Machen  
Lamy, DVM  
DACVIM (Cardiology)

**2-Dimensional Measurements**

Ao diam (cm)	1.2
LA diam (cm)	1.4
LA:Ao (Swe)	1.2
IVS thickness (cm)	0.6
LVID diastole (cm)	1.5
PW thickness (cm)	0.7
LVID systole (cm)	0.8
FS (%)	47

**Doppler Measurements**

PV Vmax (m/s)	0.6
AoV Vmax (m/s)	0.8
MR Vmax (m/s)	NM
TR Vmax (m/s)	NA
TR PG (mmHg)	NA

**IMAGING PERFORMED BY**

Pamela Harrigan,  
RDCS

**INTERPRETATION OF THE FINDINGS**

The cause of the murmur is chronic degenerative valve disease causing mild mitral regurgitation. Lack of significant left atrial enlargement indicates the current risk for complication is low. No concurrent issues such as pulmonary hypertension are noted in this study.

**HOSPITAL NAME**

Mass Veterinary Services

**REFERRING VET**

Dr. Masloski

Assessment of progression in the future will help predict long term prognosis, which is highly variable at this stage (B1).

**INVOICE**

29726

The reported blood pressure is elevated, and should be reassessed for accuracy particularly given no reported clinical signs of severe hypertension (retinal changes, etc.) or evidence of LVH on echo. Ideally obtain serial measurements in a controlled, low stress environment and continue until 3 consecutive readings plateau within 5mmHg of variability. If persistently >180mmHg despite a relatively calm demeanor, recommend institution of amlodipine to effect. Additionally if deemed accurate, screening for

**DATE**

3/21/23



**PATIENT**  
Daisy Davila

predisposing underlying causes of SHT is recommended (Cushing's, PLN, adrenal tumor, etc.), as primary disease is relatively uncommon and a rule out diagnosis.

**SPECIES**  
Canine

**BREED**  
Chihuahua Mix

**SEX**  
Female Spayed

**AGE**  
7 years

**WEIGHT**  
6.69lbs

**RECOMMENDATIONS**

- In an asymptomatic dog without significant left atrial enlargement, no cardiac medications are clearly indicated.
- Reassess BP as discussed.
- Omega fatty acid supplementation and mild salt restriction may be of some long-term benefit.
- Anesthetic risk is considered mild if needed. Cardiac protective drug choices (opioid/benzodiazepine premedication, propofol or alfaxalone induction, isoflurane gas) are recommended. Pre-oxygenate for 5-10 minutes prior to induction. Monitor for arrhythmias, hypotension, and hypoxia both intra and post-operatively and intervene as necessary. Mild IV fluid restriction is recommended to avoid fluid overload. Avoid heart rate stimulating drugs such as atropine unless clinically indicated.
- Monitor for development of a cough, labored breathing, exercise intolerance or collapse episodes.

**PLAN**

- Recommend conservative monitoring with a recheck echocardiogram in 6-12 months, sooner if any development of clinical signs.

**INTERPRETED BY**

Maggie Machen  
Lamy, DVM  
DACVIM (Cardiology)

**IMAGING PERFORMED BY**

Pamela Harrigan,  
RDCS

**HOSPITAL NAME**

Mass Veterinary  
Services

**REFERRING VET**

Dr. Masloski

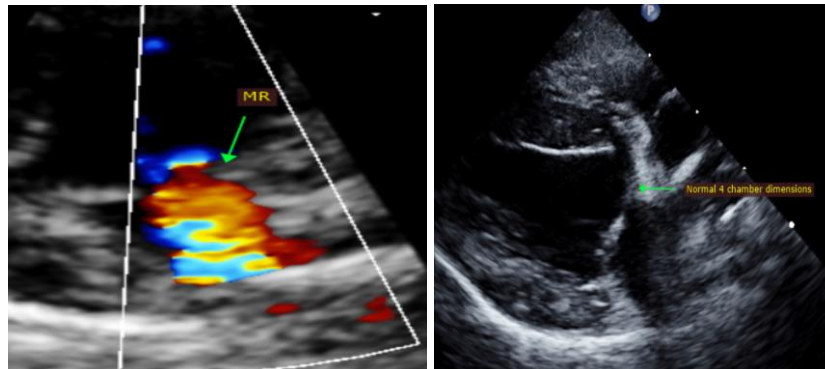
**INVOICE**

29726

**DATE**

3/21/23

**IMAGES**



The information and recommendations provided are based on the images presented by the referring veterinarian. No evaluation can be communicated regarding pathology that was not visible in the image/video clips provided.

Thank you for this referral. This report was generated using transcription software, and minor dictation errors may be present. If the clinical or image interpretation does not parallel your findings or if I can be of any further assistance, please contact me.

**Maggie Machen Lamy, DVM**

**Diplomate of the American College of Veterinary Internal Medicine (Cardiology)**  
info@sonopath.com

**Echocardiogram performed by:**

Pamela Harrigan, RDCS  
Pet Animal Ultrasound Service (4paus.com)